



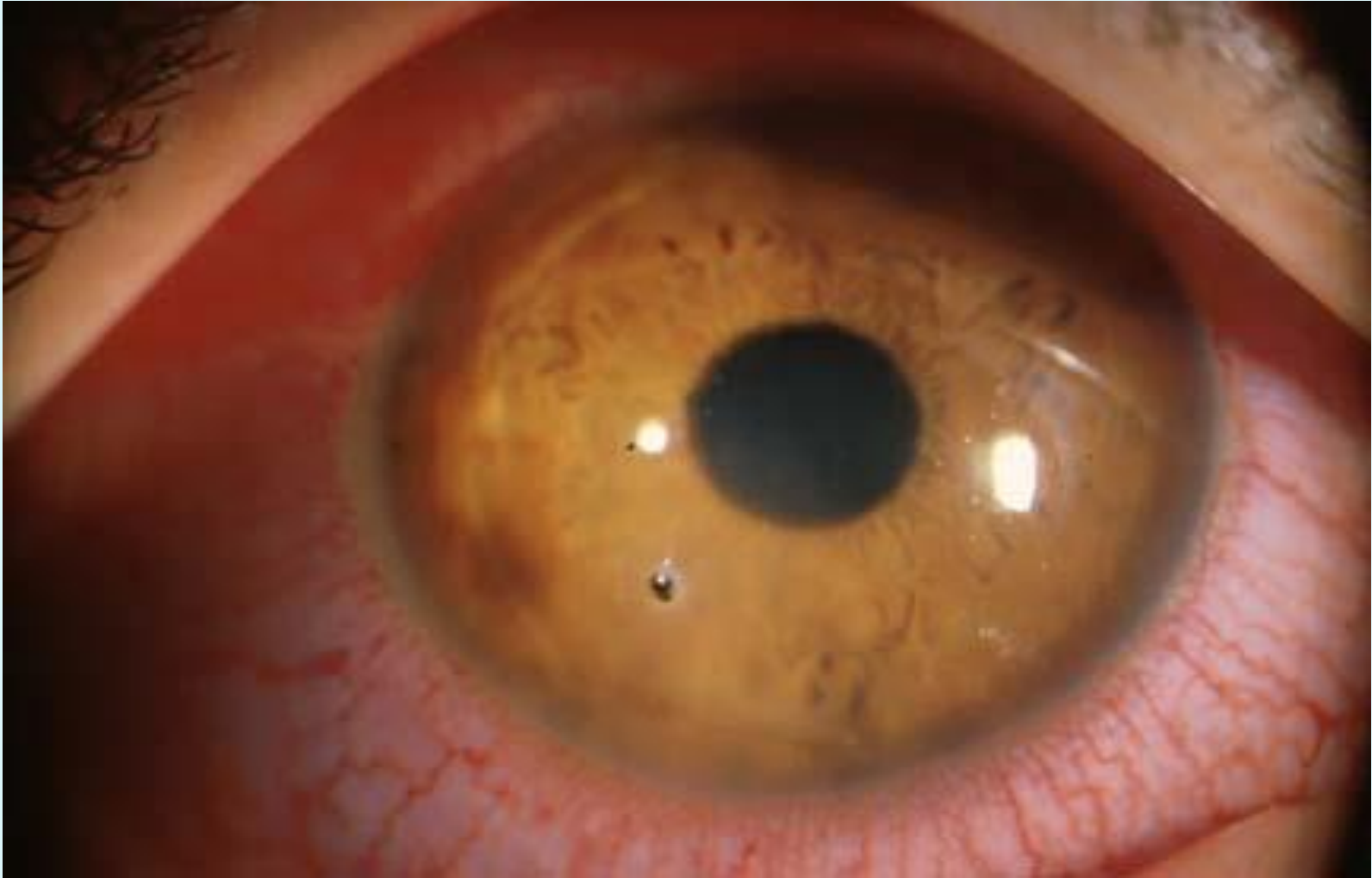# *Preventive Ophthalmology*

# Prevention of ocular injuries

- May lead to blindness or severe visual loss
- Young men and children are particularly prone to these injuries
  
- Occupational
- Nonoccupational

# Occupational injuries

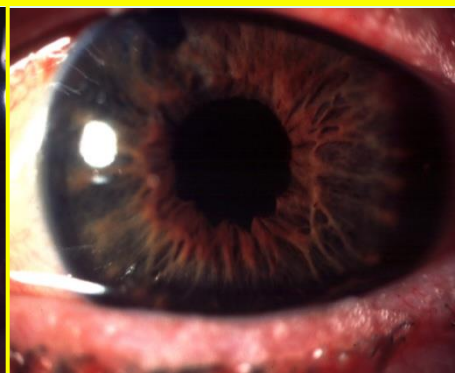- Small fragments of metal
- Tools with sharp ends
- Welding arcs
- Industrial chemicals



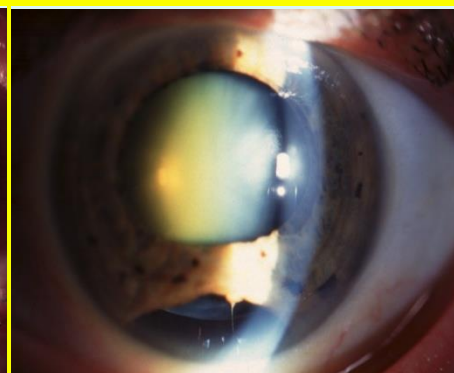# Anterior segment complications of blunt trauma



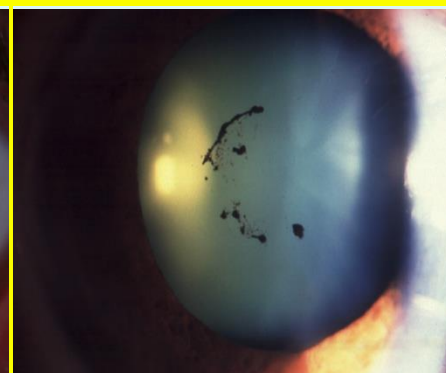
**Hyphaema**



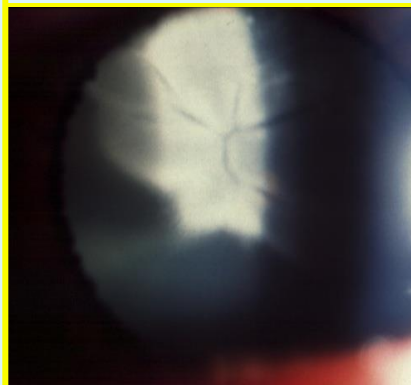
**Sphincter tear**



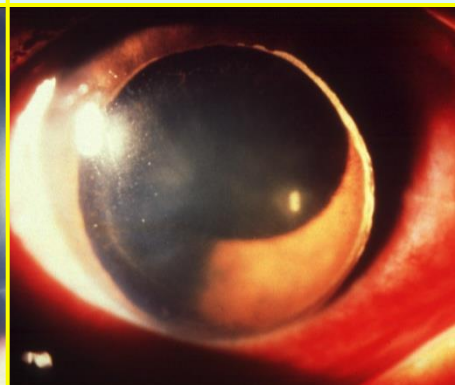
**Iridodialysis**



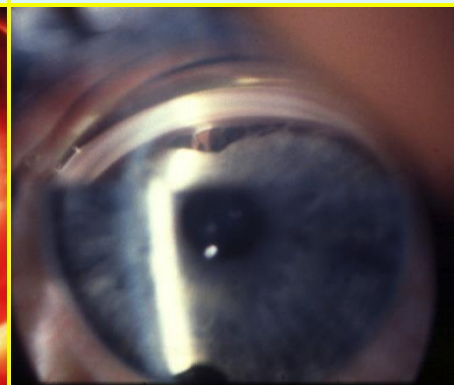
**Vossius ring**



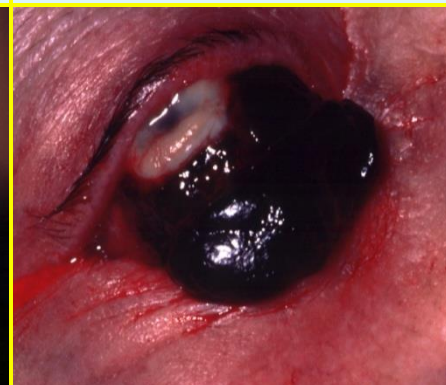
**Cataract**



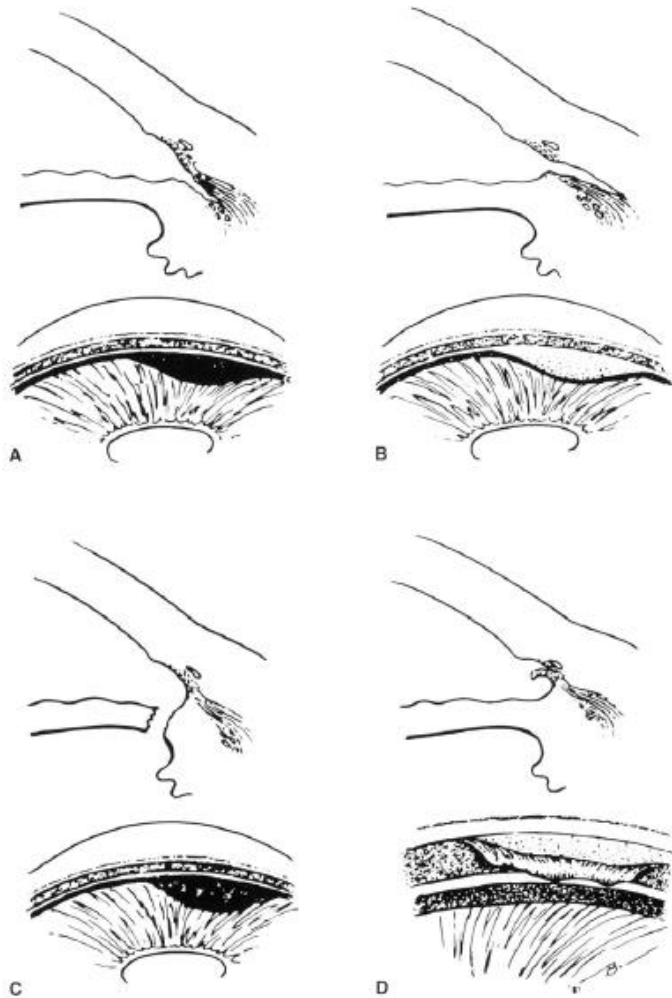
**Lens subluxation**



**Angle recession**



**Rupture of globe**




**Figure 3-9** Forms of anterior chamber angle injury associated with blunt trauma, showing cross-sectional and corresponding gonioscopic appearance. **A**, Angle recession (tear between longitudinal and circular muscles of ciliary body). **B**, Cyclodialysis (separation of ciliary body from scleral spur) with widening of suprachoroidal space. **C**, Iridodialysis (tear in root of iris). **D**, Trabecular damage (tear in anterior portion of meshwork, creating a flap that is hinged at the scleral spur). (Reproduced with permission from Shields MB. Textbook of Glaucoma, 3rd ed. Baltimore: Williams & Wilkins; 1992.)

- Workers must be properly trained in the use of tools
- Safety guards to machinery
- Safety goggles where hazards exists (even when hazardous work being performed by others)
- Education of public for works in the home

# Nonoccupational injuries

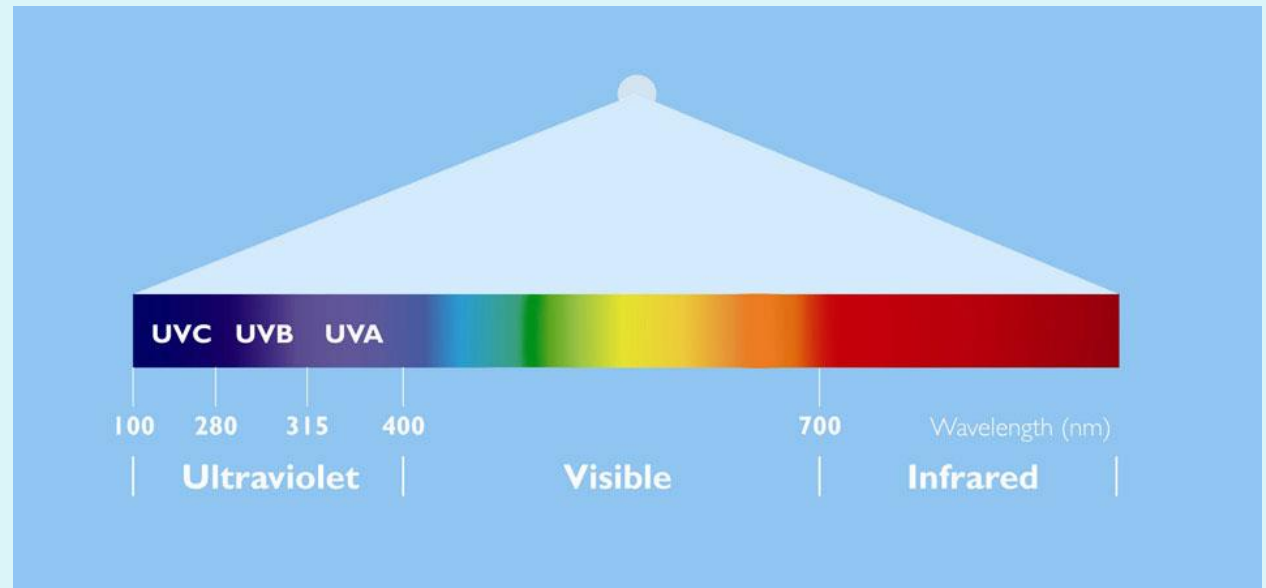
- Injuries from car accidents reduced by legislation for wearing of seat belts.
- Injuries from fireworks by limiting the availability
- Protective glasses for sports like baseball or ice hockey

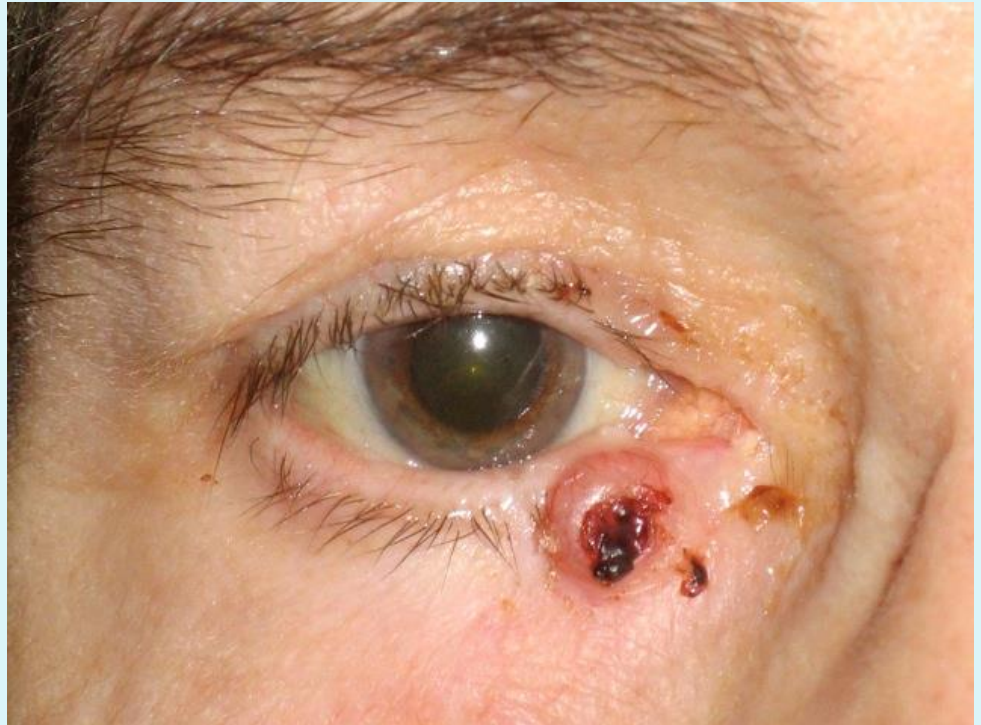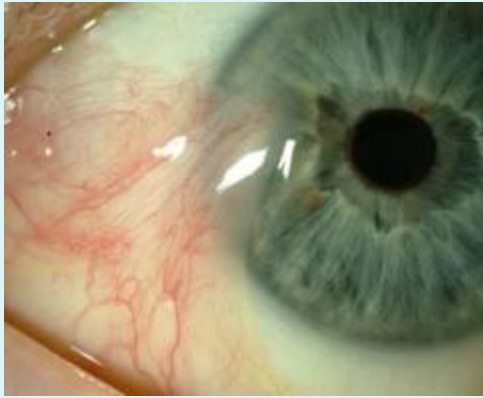


- 
- Blunt injuries while opening carbonated beverages
  - Children using pencils, scissors, knife, or ..
  - Violent assaults

# UV protection


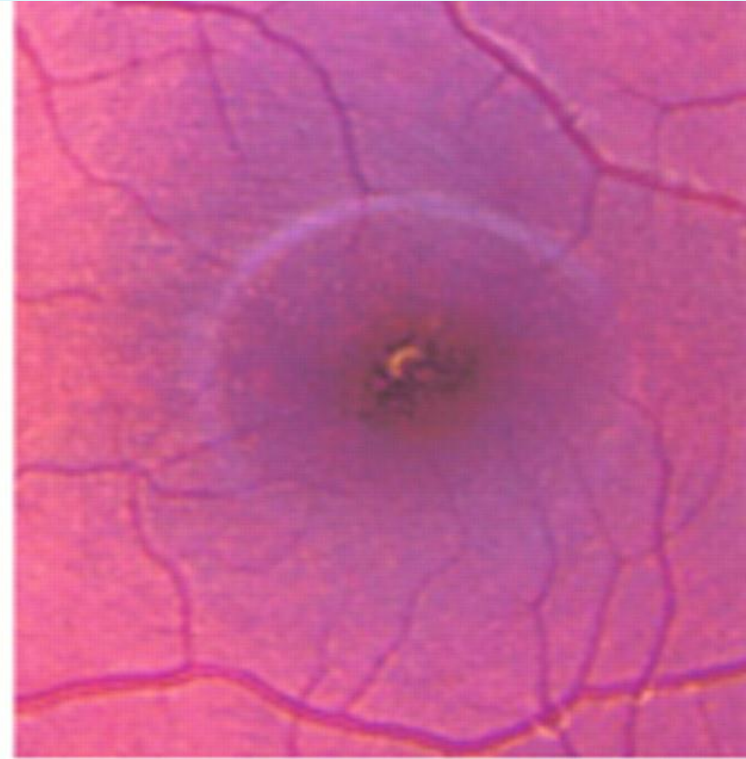
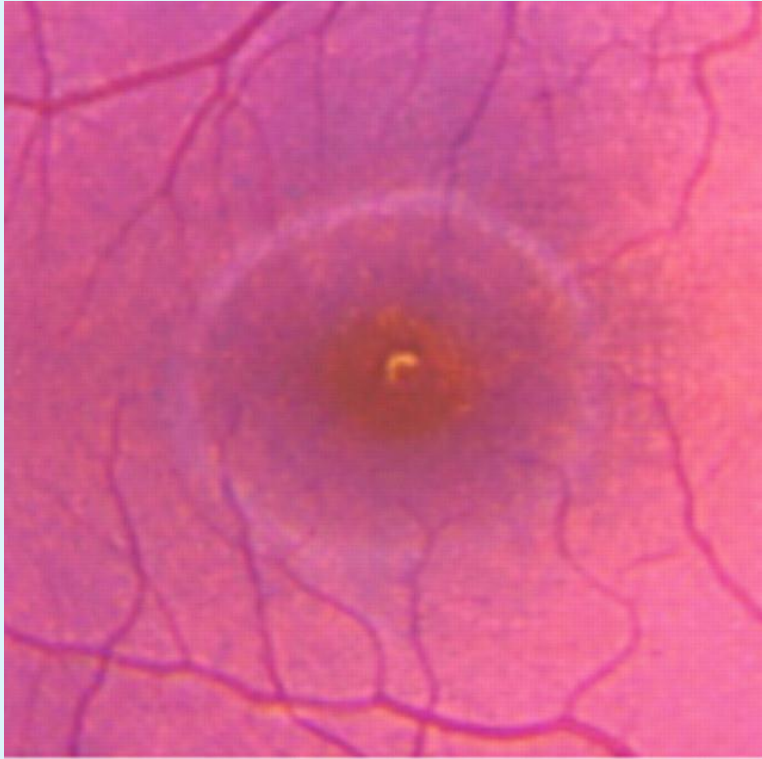
- Prevention of ARMD ??
- Prevention of cataract ??
- Prevention of Pterygium
- BCC and Melanoma of eyelids





# Eclipse retinopathy



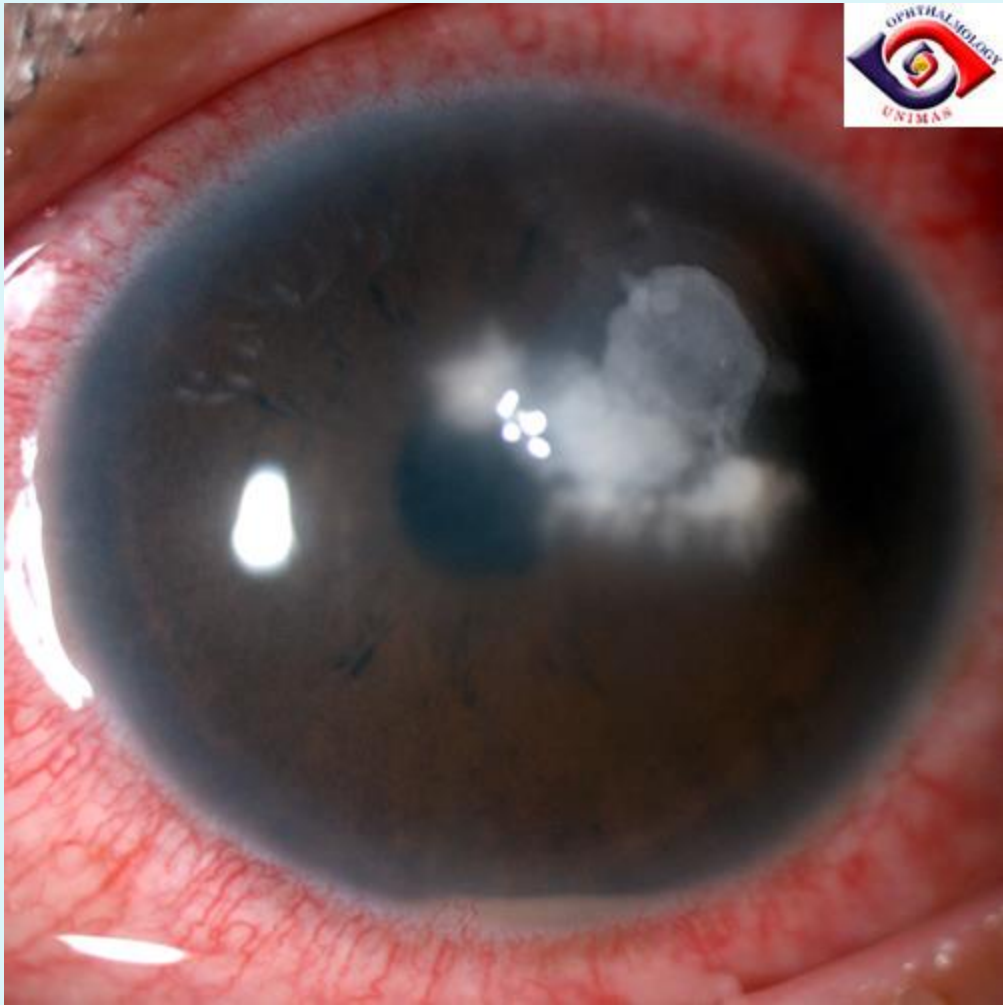

# Ocular infections

- Acquired
- Iatrogenic
- Congenital infections

# Risk with contact lenses

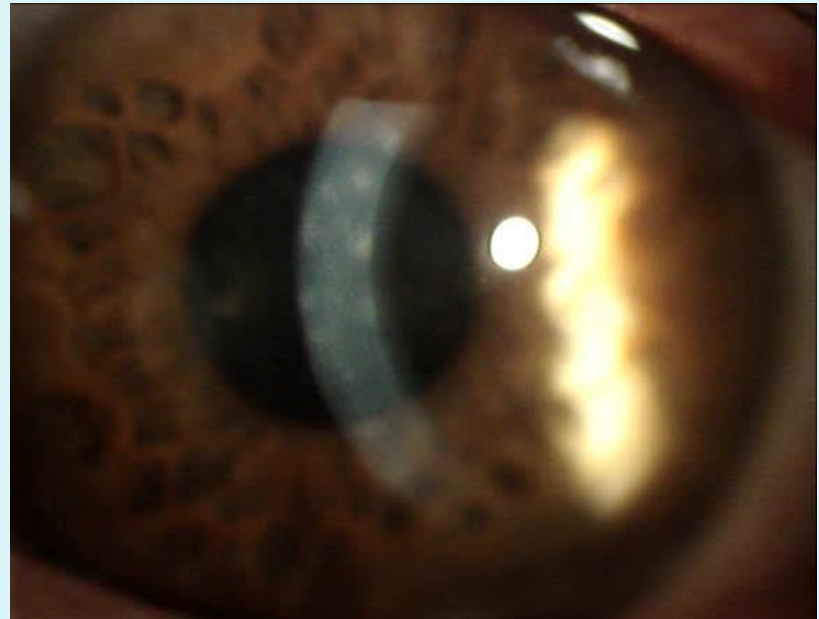- May cause suppurative keratitis
- Higher with soft lenses (extended wear)
- Patient education is important





# Iatrogenic outbreaks of EKC

- Hands
- Drops
- Tonometer



# Early detection of treatable disease

- ARMD
- POAG
- Amblyopia

# Prevention of ocular damage due to systemic diseases

- Diabetic retinopathy
- JRA



# Visual loss due to drugs